

# Standardization of adult transthoracic echocardiography reporting in agreement with recent chamber quantification, diastolic function, and heart valve disease recommendations: an expert consensus document of the European Association of Cardiovascular Imaging

**Maurizio Galderisi<sup>1\*</sup> (Chair), Bernard Cosyns<sup>2</sup> (Co-chair), Thor Edvardsen<sup>3</sup>, Nuno Cardim<sup>4</sup>, Victoria Delgado<sup>5</sup>, Giovanni Di Salvo<sup>6</sup>, Erwan Donal<sup>7</sup>, Leyla Elif Sade<sup>8</sup>, Laura Ernande<sup>9</sup>, Madalina Garbi<sup>10</sup>, Julia Grapsa<sup>11</sup>, Andreas Hagendorff<sup>12</sup>, Otto Kamp<sup>13</sup>, Julien Magne<sup>14</sup>, Ciro Santoro<sup>1</sup>, Alexandros Stefanidis<sup>15</sup>, Patrizio Lancellotti<sup>16,17</sup>, Bogdan Popescu<sup>18</sup>, and Gilbert Habib<sup>19,20</sup>**

**Reviewers:** This document was reviewed by members of the 2016–2018 EACVI Scientific Documents Committee: Frank A. Flachskampf, Bernhard Gerber, Alessia Gimelli, Kristina Haugaa.

<sup>1</sup>Interdepartmental Laboratory of Cardiac Imaging, Federico II University Hospital, Naples, Italy; <sup>2</sup>CHVZ (Centrum voor Hart en Vaatziekten)-Universitair ziekenhuis Brussel; and ICMI (In Vivo Cellular and Molecular Imaging) laboratory, Brussels, Belgium; <sup>3</sup>Department of Cardiology, Oslo University Hospital, Rikshospitalet, University of Oslo, Oslo, Norway; <sup>4</sup>Echocardiography Laboratory, Hospital da Luz, Lisbon, Portugal; <sup>5</sup>Department of Cardiology, Leiden University Medical Centre, Leiden 2300RC, The Netherlands; <sup>6</sup>Pediatric Cardiology, Royal Brompton Hospital, London, United Kingdom; <sup>7</sup>Cardiologie, LTSI-INSERM U 1099, CHU Rennes, Université Rennes 1, Rennes, France; <sup>8</sup>Baskent University, Ankara, Turkey; <sup>9</sup>Department of Physiology, INSERM U955, Université Paris-Est Creteil, Henri Mondor Hospital, DHU-ATVB, AP-HP, Créteil, France; <sup>10</sup>King's College Hospital NHS Foundation Trust, Denmark Hill, London SE5 9RS UK; <sup>11</sup>Department of Cardiovascular Sciences, Imperial College of London, London, UK; <sup>12</sup>Department of Cardiology-Angiology, Echokardiographie-Labore des Universitätsklinikums AöR, University of Leipzig, Leipzig, Germany; <sup>13</sup>Department of Cardiology, VU University Medical Center, Amsterdam, The Netherlands; <sup>14</sup>CHU Limoges, Hôpital Dupuytren, Service Cardiologie, Limoges, F-87042 France; <sup>15</sup>1st Department of Cardiology, General Hospital of Nikea, 3 P. Mela str., 184 54, Athens, Greece; <sup>16</sup>University of Liège Hospital, GIGA Cardiovascular Science, Heart Valve Clinic, Imaging Cardiology, Liège, Belgium; <sup>17</sup>Gruppo Villa Maria Care and Research, Anthea Hospital, Bari, Italy; <sup>18</sup>University of Medicine and Pharmacy 'Carol Davila'-Eurocolab, Institute of Cardiovascular Diseases, Bucharest, Romania; <sup>19</sup>Aix-Marseille Univ, URMITE, Aix Marseille Université-UM63, CNRS 7278, IRD 198, INSERM 1095; and <sup>20</sup>Cardiology Department, APHM, La Timone Hospital, Boulevard Jean Moulin, Marseille 13005, France

Received 20 September 2017; editorial decision 22 September 2017; accepted 11 October 2017; online publish-ahead-of-print 17 October 2017

## Aims

This European Association Cardiovascular Imaging (EACVI) Expert Consensus document aims at defining the main quantitative information on cardiac structure and function that needs to be included in standard echocardiographic report following recent ASE/EACVI chamber quantification, diastolic function, and heart valve disease recommendations. The document focuses on general reporting and specific pathological conditions such as heart failure, coronary artery and valvular heart disease, cardiomyopathies, and systemic diseases.

\* Corresponding author. Tel: +390817464749; Fax +390815466162. E-mail: mgalderi@unina.it

Published on behalf of the European Society of Cardiology. All rights reserved. © The Author 2017. For permissions, please email: journals.permissions@oup.com.

## Methods and results

Demographic data (age, body surface area, blood pressure, and heart rhythm and rate), type (vendor and model) of ultrasound system used and image quality need to be reported. In addition, measurements should be normalized for body size. Reference normal values, derived by ASE/EACVI recommendations, shall always be reported to differentiate normal from pathological conditions. This Expert Consensus document suggests avoiding the surveillance of specific variable using different ultrasound techniques (e.g. in echo labs with high expertise in left ventricular ejection fraction by 3D and not by 2D echocardiography). The report should be also tailored in relation with different cardiac pathologies, quality of images, and needs of the caregivers.

## Conclusion

The conclusion should be concise reflecting the status of left ventricular structure and function, the presence of left atrial and/or aortic dilation, right ventricular dysfunction, and pulmonary hypertension, leading to an objective communication with the patient health caregiver. Variation over time should be considered carefully, taking always into account the consistency of the parameters used for comparison.

## Keywords

echocardiographic report • chamber quantification • diastolic function • heart valve disease • global longitudinal strain • 3D echocardiography

## Introduction

The quantification of cardiac chamber size and function is the mainstay of echocardiographic imaging. In the recent years, echocardiographic technology has evolved with two major developments: real-time 3D echocardiography (3DE) and speckle tracking-derived myocardial deformation imaging. Nowadays, the integration of these two modalities with the standard echocardiographic Doppler tools (M-mode, 2D, colour, pulsed- and continuous-wave Doppler, and tissue Doppler imaging) substantially enriches and extends the capabilities of a comprehensive examination oriented to provide the broadest information on cardiac structure and function. At the beginning of 2015, ASE and EACVI have jointly prepared a document on the quantification of cardiac chambers, which defines the acquisition and recording methodologies of different echocardiographic modalities and establishes reference values to differentiate normal from pathological conditions.<sup>1</sup> This information can be appropriately combined with remarks provided by the more recent 2016 American Society of Echocardiography (ASE)/European Association of Cardiovascular Imaging (EACVI) recommendations on the evaluation of left ventricular (LV) diastolic function<sup>2</sup> and of valvular heart disease (VHD).<sup>3</sup>

Cardiac ultrasound operators are called to substantially update the characteristics of the echocardiographic report to highlight the importance of the new echocardiographic measurements, integrate new and traditional measurements, and formulate a comprehensive and systematic, but clinically, relevant report. This approach should be tailored in relation with different cardiac pathologies and to the needs of the patients and caregivers (cardiologists and non-cardiologists) that receive the report. Particular care needs to be taken to integrate quantitative information of chamber and haemodynamic parameters with structural (e.g. valve thickening, calcification, and prolapse) and functional (flow measurements) measurements of cardiac valves.<sup>3</sup>

The present expert consensus document of the EACVI has been designed to propose a modern echocardiographic report in line with the expectations of physicians and sonographers who operate in the fields of cardiac ultrasound.

## Left ventricle

Quantification of the LV encompasses structural measurements (LV size and mass) and functional parameters (LV global and regional systolic function and LV diastolic function).<sup>2</sup> Currently, LV size is easily obtained by measuring LV internal cavity diameters at end-diastole and end-systole by M-mode or, better, by a direct 2D approach. Information on LV structure and geometry can be finalized adding quantitative values of LV mass and relative wall thickness—derived from measurement of both internal LV cavity diameter and wall thicknesses at end diastole—which identifies LV hypertrophy and remodelling (concentric or eccentric), respectively.<sup>1</sup> These measurements are joined with determination of 2D-derived LV volumes [end-diastolic (EDV) and end-systolic (ESV)] indexed for body surface area (BSA) and LV ejection fraction (EF), a recognized hallmark for outcomes in clinical cardiology. In laboratories with proven experience, it is 'nice to have' echo determination of 3D-derived LV volumes and EF,<sup>4</sup> which do not rely on geometric assumptions, and leads to better accuracy and reproducibility in patients with good imaging quality.

Information of LV regional systolic function is necessary to be provided by visual assessment of 17 (or 18 or 16) segments wall motion score index (WMSI). LVEF and WMSI have a close inverse relation, characteristic that also allows to achieve an internal quality check inside a given echo lab. It is important to present LV segmentation scheme in the echo report since it reflects coronary perfusion territories and permits a standardized communication with other cardiac imaging techniques. A model with 17 segments (with the apical cap at the top of the other 4 apical segment: septal, inferior, lateral, and anterior) should be preferred.

Whenever possible, speckle tracking-derived global longitudinal strain (GLS) shall be obtained and reported to provide quantitative analysis of LV longitudinal function. GLS is accurate in early detection of subclinical alterations in LV longitudinal function, which occurs before LVEF impairment.<sup>5,6</sup> GLS has demonstrated to be highly feasible and reproducible in the clinical setting<sup>7</sup> and provides an incremental predictive value in unselected patients undergoing echocardiography for determination of LV function at rest.<sup>8</sup> Because of vendor (type and model) variability of speckle-tracking analysis, there is not a clear

cut-off value of GLS, but a range from -18% to -22% can be reasonable in a healthy person. Stroke volume and cardiac index are necessary, particularly in the assessment of VHD.<sup>9</sup>

According to the 2016 ASE/EACVI recommendations,<sup>2</sup> quantitative information on LV diastolic function includes at least transmitral  $E/A$  ratio and  $E$  velocity deceleration time (DT),  $e'$  velocity (average and absolute value of septal and lateral side) of the mitral annulus by pulsed tissue Doppler,  $E/e'$  ratio, and the estimate of systolic pulmonary artery pressure (sPAP) derived from tricuspid regurgitation (TR) velocity. Values of the four recommended variables for the identification of LV diastolic dysfunction—annular  $e'$  velocity, average  $E/e'$  ratio, LA volume index (LAVi), and peak TR velocity—should always be reported. Despite its controversial accuracy for LV filling pressure (LVFP) degree estimation,<sup>10</sup>  $E/e'$  ratio has a recognized value in predicting not only main cardiac events but also mortality.<sup>11,12</sup> The use of the difference between pulmonary flow-derived atrial reverse (Ar) and transmitral atrial (A) velocities duration could be considered and reported when one of more than the mentioned parameters cannot be determined or LVFP degree remain undetermined.

## Left atrium

It is important to evaluate left atrial (LA) size systematically. Because LA is an asymmetrical cavity, LA size is more accurately reflected by 2D-derived LA volume rather than area or linear dimension.<sup>1,13–15</sup> In the absence of conditions such as mitral valve disease, atrial fibrillation, athlete's heart and heart transplantation, LA volume represents the chronic burden of LVFP over time<sup>2</sup> and is strongly associated with prognosis in cardiac patients.<sup>16,17</sup> LA volume should always be indexed for BSA (LAVi).<sup>1,2</sup> 3D echocardiography, potentially more accurate in volume measurement,<sup>18</sup> is poorly applied in the clinical practice because of the lack of standardized methodology and limited normative data. Although several studies demonstrated the incremental prognostic value of LA strain in diseases such as atrial fibrillation and mitral valve disease,<sup>19,20</sup> the lack of a dedicated software and standardized methodology prevent its inclusion in a routine echocardiographic report.<sup>1–4</sup>

## Aorta

Although transthoracic echocardiography does not allow a full examination of the aorta, it helps in detecting alteration of specific segments, considering that proximal aorta is the most common area of dilation.<sup>21</sup> Diameters of annulus, aortic root (maximal diameter at sinus of Valsalva), sinotubular junction, and proximal ascending aorta are necessary to obtain a comprehensive evaluation of thoracic aortic size. Aortic annulus shall be measured by inner edge-to-inner edge diameter in mid-systole, while all other measurement shall be taken using leading edge-to-leading edge convention at end diastole.<sup>1</sup> All these diameters should be measured by 2D rather than M-mode echocardiography and normalized for body surface area.<sup>1,21</sup> Imaging and measurements of aortic arch through the suprasternal view is strongly recommended when plaque, thrombus, or dissection are suspected.<sup>22</sup>

## Right ventricle

A quantitative right ventricular (RV) assessment shall include RV basal and mid-cavity linear dimension as well as proximal and distal RV outflow tract at end diastole. Although recent findings suggest that indexing RV size to BSA may be relevant in some conditions,<sup>23–25</sup> measurements of these studies lacked reference cut-off points and frequently reported areas more than RV linear dimensions. Consequently, indexation of RV measurement is not advocated in the echo report.

Conventional assessment of RV systolic function shall comprehend at least one of the following: fractional area change (FAC), tricuspid annular plane systolic excursion (TAPSE), systolic ( $s'$ ) velocity of lateral tricuspid annulus by pulsed tissue Doppler and myocardial performance index (MPI), calculated either with pulsed Doppler of RV or with pulsed tissue Doppler of lateral tricuspid annulus. RV longitudinal strain has shown good feasibility and reproducibility<sup>26</sup> and its angle independence makes this parameter suitable for routine clinical use. Of note, RV longitudinal strain, particularly of the free wall, has shown a prognostic value in various diseases.<sup>27–30</sup> In laboratories with proper experience, 3D RV volumes (eventually normalized for BSA) and RV ejection fraction (EF), extensively validated against cardiac magnetic resonance imaging,<sup>31,32</sup> can be promoted in patients with good acoustic windows, especially when standard indices of longitudinal RV function are globally reduced and no longer representative of overall RV performance.

## Right atrium and pulmonary arterial pressure

The preferred method to report about right atrial (RA) size is 2D-derived RA volume (from the apical four-chamber view) indexed for BSA.<sup>1</sup> Similarly to LA size, RA volume is more accurate than RA linear measurements. If available, 3D RA quantification is preferable.<sup>33,34</sup> Reporting on indexed RA volumes requires two main precisions: first, 2D vs. 3D acquisition because of different normal range values (RA is usually underestimated with 2D compared with 3D) and second, gender, since normal range is lower in women than in men.<sup>35</sup> Further parameters such as sPAP and RA pressure estimation on the basis of inferior vena cava (IVC) size and collapse shall be taken into account.<sup>36</sup> According to 2015 ASE/EACVI recommendations, specific values of RA pressure rather than ranges shall be used in sPAP determination. IVC diameter and respiratory variation drive RA pressure degree determination according to recent guidelines on pulmonary hypertension.<sup>37</sup>

## Valve apparatus

When reporting echo features in VHD it is very important to provide information on the type and degree of valve dysfunction as well as on the hemodynamic burden induced by the valve defect to optimize diagnosis, stratify prognosis, and address management.

Description of left and right valve apparatus shall consider the type of valve defect. In regurgitant valve disease, 2D transthoracic echo allows to quickly differentiate severe regurgitation from minor leak.<sup>3</sup> The description of valve morphology is necessary to point out aetiology (primary/organic or secondary/functional) and mechanism of

regurgitation (normal or abnormal valve motion). Valve motion abnormalities are currently described using Carpentier's classification of leaflets motion: Type I, normal leaflets motion; Type II, excessive motion; and Type III, restrictive motion.<sup>38</sup> In addition, colour Doppler is critical to assess the regurgitation degree. Semi-quantitative [vena contracta (VC)] and quantitative [proximal isovelocity surface area (PISA)] are recommended in more than trivial regurgitation.<sup>39</sup> It is also particularly important to describe the presence and the location of calcifications and the thickness of the valves.

Transthoracic echocardiography appears to be very useful also in valve stenosis. Transvalvular peak velocities and maximum and mean pressure gradients are needed to estimate the stenosis degrees. Whenever possible, the evaluation of valve area by continuity equation is needed since loading condition influence transvalvular velocity and pressure gradient. Additional information on stroke volume/stroke volume index and LV filling pressure are necessary.<sup>40</sup>

In both regurgitant and stenotic valve diseases, the haemodynamic effects on ventricles and atria, as well as the estimation of sPAP, shall to be always analysed and reported (see section dedicated to VHD). In the presence of VHD, 3D echocardiography provides additional information on valve apparatus and its relation with other cardiac structures (especially for mitral valve disease). However, 3D echocardiography is strongly limited by lower spatial resolution compared with 2D images and to the level of expertise of individual operators.<sup>41</sup>

## How to focus echo report in different diseases

### In patients with heart failure

The 2016 ESC guidelines on heart failure (HF) consider other cardiac imaging tests only when 'echo images are suboptimal or an unusual cause of heart failure is suspected'.<sup>42</sup> In HF patients, for the best diagnosis establishment and treatment strategy decision, measurements of LV structure, systolic, and diastolic function as well as estimated RV function and sPAP degree are mandatory<sup>1,2</sup> in the echo report. In the 2016 ESC guidelines, HF with preserved EF is defined as an LVEF  $\geq 50\%$  and patients with an LVEF between 40% and 49% are considered in a grey zone, which is defined as HF with mid-range EF.<sup>42</sup> Accordingly, this terminology shall be applied in the echo report. Important functional alterations, suggested by ESC guidelines, such as  $E/e'$  ratio  $\geq 14$  and average  $e'$  velocity  $< 9$  cm/s<sup>42</sup> shall also be highlighted. Other strongly encouraged parameters include LVGLS, 3D LV volumes and EF, RV free-wall longitudinal strain—despite controversial<sup>43</sup>—and RV fractional area change. Among these parameters, particular emphasis shall be reserved for LV GLS and 3D LVEF. LV GLS can be in fact altered as a sign of LV longitudinal dysfunction, particularly in HF with preserved LVEF, a condition in which an early diagnosis can have important reflections in the patient's management.<sup>44</sup> LV GLS has demonstrated the ability for a subclinical detection of LV dysfunction in several clinical conditions including anticancer drug-related cardiotoxicity<sup>44</sup> and has a recognized prognostic value in HF with both reduced and preserved LVEF.<sup>45–48</sup> A cut-off value upon  $-18\%$  (although magnitudes are vendor dependent)<sup>1</sup> can be expected to indicate normal LV longitudinal systolic function. The use of 3D echo-derived LV volumes and EF becomes particularly crucial in

candidates for implantable cardioverter defibrillator (ICD)/cardiac resynchronization therapy (CRT) because of its intrinsic better reproducibility when compared with 2D EF.<sup>49</sup> The 35% cut-off point of LVEF can be considered more accurate using 3D than 2D echocardiography and drive appropriate choices in this clinical setting.

The description of the mechanical dyssynchrony (septal flash, apical rocking assessed qualitatively, and or quantitatively using longitudinal strain data) can be utilized in candidates to CRT but remain still controversial to be included in the echo report. Optional measurements include LV sphericity index (long axis/short axis), LV and RV pre-ejection time (determined by pulsed Doppler), duration of LV filling (mitral inflow duration), and 3D-derived RVEF.

### In patients with coronary artery disease

Reporting information on LV global and regional systolic function is mandatory in patients with coronary artery disease (CAD). Two or 3D LV EDV and ESV shall be calculated and LVEF derived. When available, LV GLS shall be considered in the echo report of all CAD patients, in particular in acute coronary syndromes. LV GLS is early impaired in the presence of acute and chronic myocardial ischemia<sup>5</sup> and provides a significant incremental value for identifying patients with LV subclinical dysfunction over pre-test likelihood of CAD.<sup>50</sup> It also predicts recovery of LV systolic function after acute myocardial infarction<sup>51</sup> and has a recognized incremental prognostic value over LVEF in chronic CAD<sup>52</sup> and acute myocardial infarction.<sup>53</sup>

Regional LV systolic function needs to be assessed in the model with 17 segments reflecting coronary perfusion territories. Semi-quantitative evaluation of regional motion (1 = normokinesis, 2 = hypokinesis, 3 = akinesis, and 4 = dyskinesis) shall be used to calculate WMSI.

Other parameters of prognostic relevance include measurements of LV diastolic function—mainly transmitral  $E/A$  ratio,  $E$  velocity DT,  $e'$  velocity,  $E/e'$  ratio, and LAVi according to 2016 recommendations<sup>2</sup>—and indexes of RV systolic function (TAPSE or  $s'$  velocity of lateral tricuspid annulus). An  $E$  velocity DT  $< 130$  ms and an  $E/e'$  ratio  $> 15$  should be reported as remarkable adverse prognosticators after acute myocardial infarction.<sup>11</sup>

LV mechanical dispersion based on 2D speckle tracking, calculated as the standard deviation of the time to peak longitudinal strain of 16 LV segments, has been demonstrated to predict arrhythmic events independently of LVEF after acute myocardial infarction.<sup>54</sup>

### In patients with valvular heart disease

In VHD descriptive morphological findings of the valves<sup>3</sup>—which always need to be well delineated in the echo report—and traditional calculated measurements have to be integrated into a concise and conclusive echo report. Because VHD mainly affects geometry and function of cardiac cavities, the neighbouring cavities shall be accurately assessed with respect to size and function, e.g. LV and LA for mitral valve diseases, LV and aortic root, and proximal ascending aorta for aortic valve diseases.

In general, haemodynamic alterations in chronic VHD should be reported to characterize different stages and alterations of myocardial function that are related to disease. In left VHD, the quantitative assessment of LV diameters, volumes, and EF as well  $E/e'$  ratio and sPAP is mandatory. LV GLS, often preceding LVEF reduction, is nice to have for detecting subclinical alteration and predicting postoperative recovery of LV function.<sup>55,56</sup>

To characterize LV remodelling in chronic mitral and aortic valve diseases measures as sphericity index (calculated as LV short-to-long-axis dimension ratio at end diastole in apical four-chamber view), with a cut-off value of 0.76,<sup>57</sup> could be given. LV total and effective stroke volume should be determined by LV volumes and, additionally, by measuring LV outflow tract (LVOT) cross-sectional area and pulsed Doppler-derived velocity time integral ( $VT_{LVOT}$ ) to check the correctness of LV volume measurements and to estimate regurgitant volumes in the presence of valve regurgitation. In aortic stenosis, 3D echocardiography may provide an accurate assessment of LVOT area thus avoiding underestimation due to geometric circular assumption.<sup>40</sup> Measurement of tricuspid annular diameter in mid-systole is mandatory in left-sided heart diseases with surgical indication (cut-off point for tricuspid annuloplasty = 40 mm). LA size and function shall be evaluated in all patients with mitral valve diseases by 2D or 3D assessment. In patients with aortic valve disease, dimensions of LVOT, aortic annulus, aortic root, sinotubular junction, and proximal ascending aorta shall be reported, better if indexed for BSA.<sup>3</sup> In patients with tricuspid and pulmonary valvular diseases, echocardiographic evaluation shall focus on sizes and function of the right heart chambers. Especially for the evaluation of tricuspid valvular diseases, 3D echocardiographic quantification of RV volumes and EF is nice to have.<sup>1</sup>

### In patients with cardiomyopathies

2D left and right ventricular dimensions shall always be measured in patients with cardiomyopathies, not only for their diagnostic value but also for their well-known prognostic impact.<sup>58,59</sup> It is necessary to include 2D measurements of wall thickness (e.g. in patients with asymmetric hypertrophy additional information on septal morphology and wall hypertrophy localization are required) and cavity diameters, 2D or 3D measurements of volume and LVEF. Description of myocardial aspect (sparkling of myocardial wall, hyper-trabeculation) are needed to differentiate various kind of cardiomyopathies. Three-dimensional echocardiography should be preferred for quantifying LV mass in abnormally shaped ventricles or in patients with asymmetric hypertrophy.<sup>59</sup> Linear and volumetric measurements shall be indexed for BSA to avoid misdiagnosis. Additionally, 3D assessment of LVOT is recommended in obstructive hypertrophic cardiomyopathy, when septal reduction therapy is indicated.<sup>59</sup>

The assessment of LV GLS should be considered in patients with cardiomyopathies because of its incremental value over conventional methods.<sup>59</sup> In some cardiomyopathies, the distribution of regional longitudinal strain can represent an argument in favour of an aetiological diagnosis (e.g. apical sparing in cardiac amyloidosis).<sup>60,61</sup> In particular, RV strain of the free wall (three segments) is nice to have in arrhythmogenic ventricular cardiomyopathy, where a decrease has been shown in early disease stages.<sup>62</sup>

### In patients with systemic diseases and suspected cardiac involvement

Numerous systemic diseases such as arterial systemic hypertension, diabetes mellitus, obesity, haemochromatosis, sarcoidosis, systemic sclerosis, storage disorders (e.g. Fabry, Pompe) endomyocardial fibrosis, and others can affect the heart. Since signs of cardiac involvement by systemic disorders can be subtle, a comprehensive report of quantitative parameters is required. The report shall include 2D

measurements of wall thickness, volume, and cavity diameters, with calculation of LV mass for diagnosis of LV hypertrophy, LV and RV systolic parameters as well as measurements of LV diastolic function. Echocardiographic measurements to be considered in hypertensive patients are comprehensively delineated in ASE/EACVI recommendations on the use of echocardiography in adult hypertension.<sup>63</sup> LV mass index is always necessary, as it is a recognized prognostic factor in arterial systemic hypertension.<sup>64</sup> Values of LV mass shall always be indexed for BSA, but studies suggest that indexing to height powered to 2.7 or 1.7 has the advantages to better identify the rate of LV hypertrophy and prognosis in overweight/obese patients.<sup>65,66</sup> Calculation of relative wall thickness allows categorization of LV mass increase as either concentric (relative wall thickness >0.42) or eccentric ( $\leq 0.42$ ) hypertrophy as well as the identification of concentric remodeling (normal LV mass + increased relative wall thickness).<sup>1</sup>

Quantitative information on LV diastolic function shall be considered in systemic heart disease. Abnormally increased  $E/e'$  ratio is suggestive of primary cardiac events in uncomplicated hypertensive patients.<sup>12</sup> Although LV EF is normal in the vast majority of systemic heart diseases, LV GLS could provide a useful evaluation of early, sub-clinical changes of systolic function in this setting, particularly in hypertensive and diabetic patients.<sup>67,68</sup>

### Key points

- In patients with suspected or ascertained HF, the echo examination needs to be very comprehensive, including quantitative information on LVEF, longitudinal function (preferably GLS), LV diastolic function and LVFP as well as pulmonary pressure degree and RV function.
- In patients with CAD, assessment of LV global and regional systolic function shall be routinely reported. Global and regional longitudinal function can provide additional information in this clinical setting. Diastolic parameters also have a recognized value. In VHD, valve morphological findings shall be well integrated with highlights on geometry and function of the cardiac cavity that reflects the haemodynamic burden of the valvular disease.
- In patients with cardiomyopathies, the report shall include 2D measurements of wall thickness and cavity diameters, 2D or 3D measurements of volumes and LVEF as well as GLS and diastolic parameters.
- In patients with systemic heart disease, the report shall include 2D measurements of wall thickness and cavity diameters, 2D or 3D measurements of LV volume and EF with calculation of LV mass for diagnosis of LV hypertrophy.

### Main points of the echo report

Primarily, referral diagnosis or reason of the echo examination and demographic data such as age, body height, and weight are mandatory on the echo report. In particular, Doppler parameters of diastolic and systolic function—including pulsed tissue Doppler—<sup>69,70</sup> but also LV GLS<sup>71,72</sup>—are all strongly age dependent, and their values shall therefore be considered carefully in relation with the age of a given patient.

The reporting of type of echo machine used (vendor and model) is necessary. The inter-vendor and software variability of advanced echo parameters currently used—mainly LV GLS<sup>73</sup> is well recognized and even a similar variability of some standard echo parameters (mainly those obtainable by pulsed Tissue Doppler) cannot be excluded *a priori*.

It is important to report the quality of cardiac imaging recorded, possibly grading as optimal, fair, suboptimal, and poor. A judgement of the examination quality is important as the lack of some parameters can lead to inconclusive diagnosis when the quality of the images is suboptimal/poor. Under these circumstances, the use of advanced echo techniques such as strain and 3D may become misleading.

Some important measurements (e.g. LV internal cavity diameters, LV mass, and LA volume) need to be normalized for BSA (which can be obtained by height and weight). In addition, blood pressure and both heart rhythm and rate at the time of the echocardiographic examination are also mandatory. In patients who undergo dialysis status of 'post- or pre-dialysis' should also be mentioned. LV and RV

functional parameters are strongly influenced by changes in afterload and even LV GLS is subjected to variations of both systolic and diastolic BP.<sup>67,68</sup> It is also well recognized how all Doppler measurements of diastolic function are extremely variable in relation to changes in heart rate.<sup>74</sup> In patients with sinus tachycardia, a transmitral *E/A* ratio cannot be ascribed to LV abnormal relaxation pattern and is in fact associated with a very short *E* velocity deceleration time (conversely prolonged in the case of abnormal relaxation). Obviously, also the type of rhythm (sinus, atrial fibrillation, and repetitive premature beats) can influence systolic and diastolic measurements. Accordingly, reporting heart rhythm and rate may produce substantial changes in the interpretation of the echo results.

The 2015 chamber quantification recommendations present the reference normal and abnormal values of all the described parameters.<sup>1</sup> Therefore, cut-off points of the echo parameters address a clinical diagnosis on the state of cardiac structure and function. *Table 1* is summarizing the reference values of the main chamber parameters and LV diastolic measurements. The main echo parameters obtainable with advanced echo techniques and their reference values are described in *Table 2*. The mention of clear cut-off points of normalcies is a key point to guide the report conclusions and permits to orientate the readers for an appropriate diagnosis. The grading of the severity of abnormality with terms such as mild, moderate, and severe—available in the recommendations—can be applied in the conclusions of the report. Another key point is to avoid the repetition of the same echocardiographic parameter obtained with different techniques (e.g. LVEF or LAVi with 2D and 3D echocardiography) in the report. The operator has the opportunity to choose the most accurate and reproducible technique in individual patients considering the given disease and the technology availability. For instance, LV GLS is the best parameter for quantifying LV longitudinal function but, if speckle tracking is not available, acceptable information on LV longitudinal function can be provided by pulsed tissue Doppler-derived *s'* velocity of the mitral annulus or even by the simple M-mode-derived MAPSE (average of septal and lateral sides). 3D echocardiography is preferable for quantification of LVEF in patients with present crucial range values (between 30% and 40%) to drive the best management.

*Figure 1* summarizes an EACVI proposal for an echo report, which needs, however, always to be tailored to individual patients, pathological conditions, and quality of the images. Whenever speckle-tracking technology is not available, LV GLS and RV free-wall LS can be replaced by pulsed tissue Doppler-derived *s'* velocity of mitral and tricuspid annulus, respectively.

**Table 1** Standard echocardiographic and Doppler measurements

Chamber	Parameter	Normal values
Left ventricle	LV end-diastolic dimension (mm)	≤58.4 (M), ≤52.2 (F)
	LV end-systolic dimension (mm)	≤39.8 (M), ≤34.8 (F)
	LV EDV index (mm <sup>3</sup> /m <sup>2</sup> )	<75 (M), <62 (F)
	LV ESV index (mm <sup>3</sup> /m <sup>2</sup> )	<32 (M), <25 (F)
	Relative wall thickness	≤0.42
	LVM index (g/m <sup>2</sup> )	≤102 (M), ≤88 (F)
	LVEF, biplane (%)	≥52 (M), ≥54 (F)
	Transmitral <i>E</i> velocity (cm/s)	<50
	Transmitral <i>E</i> velocity DT (ms)	>160 to <220
	Transmitral <i>E/A</i> ratio	>0.8 to <2.0
Left atrium	Septal annular <i>e'</i> velocity (cm/s)	>7
	Lateral annular <i>e'</i> velocity (cm/s)	>10
	LV <i>E/e'</i> (average) ratio	<14
Thoracic aorta	Maximal LAVi (mL/m <sup>2</sup> )	≤34
Thoracic aorta	Annulus (cm/m <sup>2</sup> )	≤1.4 (M and F)
	Sinus of Valsalva (cm/m <sup>2</sup> )	≤1.9 (M), ≤2.0 (F)
	Sinotubular junction (cm/m <sup>2</sup> )	≤1.7 (M and F)
Right ventricle	Proximal ascending aorta (cm/m <sup>2</sup> )	≤1.7 (M), ≤1.9 (F)
	RV basal diameter (mm)	<42
	RV mid diameter (mm)	<36
Right ventricle	RVOT proximal diameter (mm)	<36
	RVOT distal diameter (mm)	<28
	TAPSE (mm)	>17
	Tricuspid annular <i>s'</i> velocity (cm/s)	>9.5
	Fractional area change (%)	>35
Right atrium	RAVi (mL/m <sup>2</sup> )	<30 (M), <28 (F)

DT, deceleration time; *E*, transmitral early diastolic velocity; *e'*, mitral annular early diastolic velocity; EDV, end-diastolic volume; EF, ejection fraction; ESV, end-systolic volume; LAVi, left atrial volume index; LV, left ventricular; LVM, left ventricular mass; RAVi, right atrial volume index; RV, right ventricular; RVOT, right ventricular outflow tract; TAPSE, tricuspid annular plane systolic excursion.

**Table 2** Advanced echocardiographic parameters

Chamber	Parameter	Normal values
Left ventricle	LV GLS (%)	>20% <sup>a</sup>
	3D EDV index (mL/m <sup>2</sup> )	<80 (M), <72 (F)
	3D ESV index (mL/m <sup>2</sup> )	<33 (M), <29 (F)
	3D LVEF (%)	>54 (M), >57 (F)
Right ventricle	Free wall GLS	>23% <sup>a</sup>

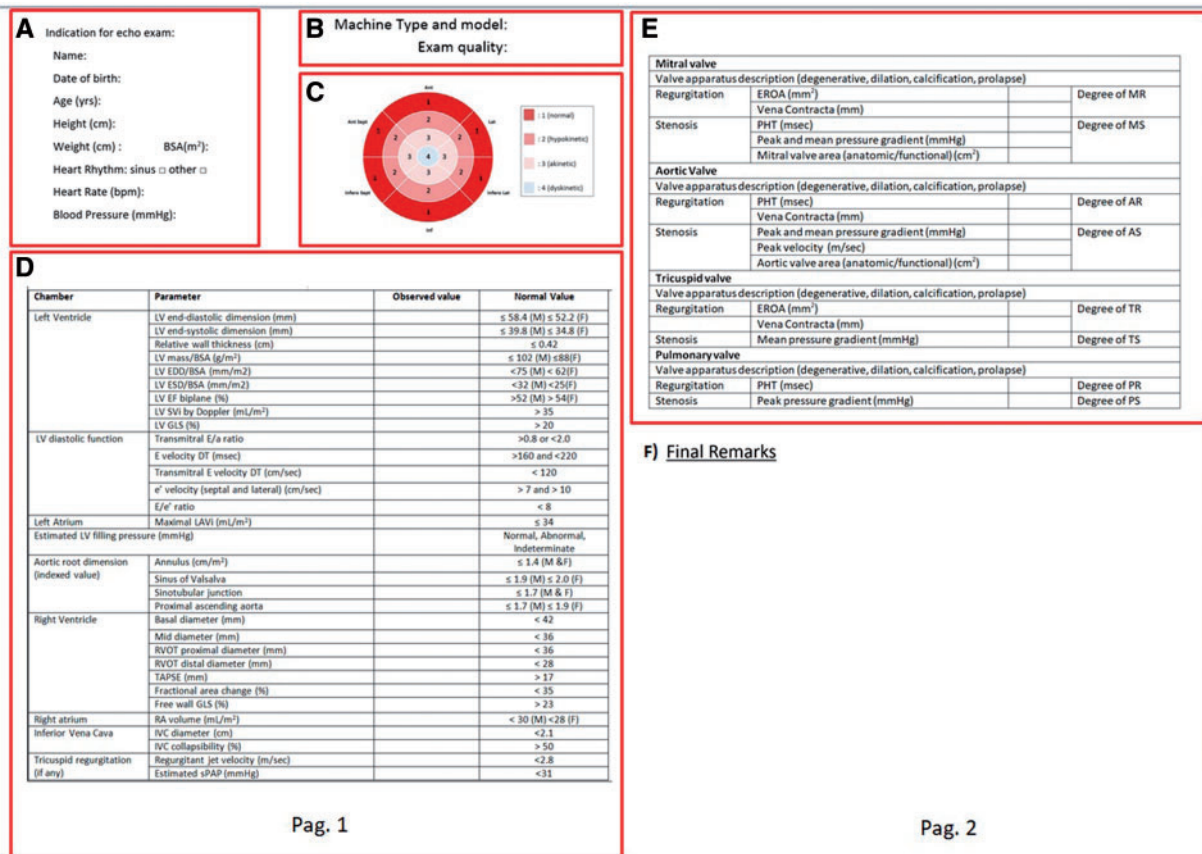
<sup>a</sup>Expressed in absolute value despite of negative sign. EDV, end-diastolic volume; EF, ejection fraction; ESV, end-systolic volume; GLS, global longitudinal strain; LV, left ventricular; RV, right ventricular.

### Key points

- Demographic data, type (vendor and model) of machine, and quality of imaging always need to be reported.
- The adjustment of some important measurements for body size is needed.
- The report shall include normal reference values to differentiate normal from pathological conditions.
- It is suggested to avoid the report of the same parameter using different ultrasound techniques.

### Conclusions of the echo report

The conclusions of the report shall be concise, but also conclusive, whenever possible, for the diagnosis of the main pathology in a given patient. The conclusions shall answer to the clinical question and be clinically driven and oriented towards the disease management and treatment. The abnormal findings shall be highlighted first. Information on the state of LV structure and function (systolic and diastolic) and LVFP estimate, more than the simple categorization of LV diastolic patterns, shall be reported. Information on the presence of LA and/or aortic dilation, RV systolic dysfunction, and pulmonary arterial hypertension is always needed. The advent of novel ultrasound techniques introduces detailed quantitative measurements



**Figure 1** EACVI proposal for an echo report according to 2015 chamber quantification and 2016 diastolic function recommendations. Qualitative and quantitative information on structure and function shall be added when needed. In the valve assessment state as “normal” in absence of abnormalities. (A) Anagraphic and biometric data, (B) vendor and images quality, (C) bull's-eye of regional wall motion, (D) quantitative analysis, (E) valve description and function, and (F) final remarks. \* LVFP is normal if 2 on 3 marked diastolic parameters are normal. LV EDV and ESV performed by 3D echocardiography if possible TAPSE could be eventually replaced by s' velocity of lateral tricuspid annulus LV GLS and RV GLS expressed in absolute values. AR, aortic regurgitation; AS, aortic stenosis; BSA, body surface area; EDD, end-diastolic diameter; EDV, end-diastolic volume; EF, ejection fraction; EROA, effective regurgitant orifice area; ESD, end-systolic diameter; ESV, end-systolic volume; GLS, global longitudinal strain; IVC, inferior vena cava; LAVi, left atrial volume index; LV, left ventricular; LVFP, left ventricular filling pressure; MR, mitral regurgitation; MS, mitral stenosis; PHT, pressure half time; PR, pulmonary regurgitation; PS, pulmonary stenosis; RA, right atrial; RAVI, right atrial volume index; RV, right ventricular; RVOT, right ventricular outflow tract; sPAP, systolic pulmonary arterial pressure; SVi, stroke volume index; TAPSE, tricuspid annular plane systolic excursion; TR, tricuspid regurgitation; TS, tricuspid stenosis.



27. Verhaert D, Mullens W, Borowski A, Popovic ZB, Curtin RJ, Thomas JD *et al*. Right ventricular response to intensive medical therapy in advanced decompensated heart failure. *Circ Heart Fail* 2010;**3**:340–6.
28. Guendouz S, Rappeneau S, Nahum J, Dubois-Rande JL, Gueret P, Monin JL *et al*. Prognostic significance and normal values of 2D strain to assess right ventricular systolic function in chronic heart failure. *Circ J* 2012;**76**:127–36.
29. Antoni ML, Scherptong RW, Atary JZ, Boersma E, Holman ER, van der Wall EE *et al*. Prognostic value of right ventricular function in patients after acute myocardial infarction treated with primary percutaneous coronary intervention. *Circ Cardiovasc Imaging* 2010;**3**:264–71.
30. Hardegree EL, Sachdev A, Villarraga HR, Frantz RP, Mc Goon MD, Kushwaha SS *et al*. Role of serial quantitative assessment of right ventricular function by strain in pulmonary arterial hypertension. *Am J Cardiol* 2013;**111**:143–8.
31. Shimada YJ, Shiota M, Siegel RJ, Shiota T. T. Accuracy of right ventricular volumes and function determined by three-dimensional echocardiography in comparison with magnetic resonance imaging: a meta-analysis study. *J Am Soc Echocardiogr* 2010;**23**:943–53.
32. Sugeng L, Mor-Avi V, Weinert L, Niel J, Ebner C, Steringer-Mascherbauer R *et al*. Multimodality comparison of quantitative volumetric analysis of the right ventricle. *JACC Cardiovasc Imaging* 2010;**3**:10–8.
33. Peluso D, Badano LP, Muraru D, Dal Bianco L, Cucchini U, Kocabay G *et al*. Right atrial size and function assessed with three-dimensional and speckle-tracking echocardiography in 200 healthy volunteers. *Eur Heart J Cardiovasc Imaging* 2013;**14**:1106–14.
34. Quraini D, Pandian NG, Patel AR. Three-dimensional echocardiographic analysis of right atrial volume in normal and abnormal hearts: comparison of biplane and multiplane methods. *Echocardiography* 2012;**29**:608–13.
35. Moreno J, Pérez de Isla L, Campos N, Guinea J, Domínguez-Perez L, Saltijeral A *et al*. Right atrial indexed volume in healthy adult population: reference values for two-dimensional and three-dimensional echocardiographic measurements. *Echocardiography* 2013;**30**:667–71.
36. Rudski LG, Lai WW, Afilalo J, Hua L, Handschumacher MD, Chandrasekaran K *et al*. Guidelines for the echocardiographic assessment of the right heart in adults: a report from the American Society of Echocardiography endorsed by the European Association of Echocardiography, a registered branch of the European Society of Cardiology, and the Canadian Society of Echocardiography. *J Am Soc Echocardiogr* 2010;**23**:685–713.
37. Galiè N, Humbert M, Vachiery JL, Gibbs S, Lang I, Torbicki A *et al*. 2015 ESC/ERS Guidelines for the diagnosis and treatment of pulmonary hypertension: the Joint Task Force for the Diagnosis and Treatment of Pulmonary Hypertension of the European Society of Cardiology (ESC) and the European Respiratory Society (ERS); endorsed by: Association for European Paediatric and Congenital Cardiology (AEPC), International Society for Heart and Lung Transplantation (ISHLT). *Eur Heart J* 2016;**1**:67–119.
38. Carpentier A, Chauvaud S, Fabiani JN, Deloche A, Relland J, Lessana A *et al*. Reconstructive surgery of mitral valve incompetence: ten-year appraisal. *J Thorac Cardiovasc Surg* 1980;**79**:338–48. 6.
39. Vahanian A, Alfieri O, Andreotti F, Antunes M, Baron-Esquivias G, Baumgartner H *et al*. Guidelines on the management of valvular heart disease (version 2012): the Joint Task Force on the Management of Valvular Heart Disease of the European Society of Cardiology (ESC) and the European Association for Cardio-Thoracic Surgery (EACTS). *Eur Heart J* 2012;**33**:2451–96.
40. Baumgartner H, Hung J, Bermejo J, Chambers JB, Edvardsen T, Goldstein S *et al*. Recommendations on the echocardiographic assessment of aortic valve stenosis: a focused update from the European Association of Cardiovascular Imaging and the American Society of Echocardiography. *Eur Heart J Cardiovasc Imaging* 2017;**18**:254–75.
41. Lang RM, Badano LP, Tsang W, Adams DH, Agricola E, Buck T *et al*. EAE/ASE recommendations for image acquisition and display using three-dimensional echocardiography. *Eur Heart J Cardiovasc Imaging* 2012;**13**:1–46.
42. Ponikowski P, Voors AA, Anker SD, Bueno H, Cleland JG, Coats AJ *et al*. 2016 ESC Guidelines for the diagnosis and treatment of acute and chronic heart failure: the Task Force for the diagnosis and treatment of acute and chronic heart failure of the European Society of Cardiology (ESC). Developed with the special contribution of the Heart Failure Association (HFA) of the ESC. *Eur J Heart Fail* 2016;**18**:891–975.
43. Damiano RJ Jr, La Follette P Jr, Cox JL, Lowe JE, Santamore WP. Significant left ventricular contribution to right ventricular systolic function. *Am J Physiol* 1991;**261**:1514–24.
44. Plana JC, Galderisi M, Barac A, Ewer MS, Ky B, Scherrer-Crosbie M *et al*. Expert consensus for multimodality imaging evaluation of adult patients during and after cancer therapy: a report from the American Society of Echocardiography and the European Association of Cardiovascular Imaging. *Eur Heart J Cardiovasc Imaging* 2014;**15**:1063–93.
45. Sengeløv M, Jørgensen PG, Jensen JS, Bruun NE, Olsen FJ, Fritz-Hansen T *et al*. Global longitudinal strain is a superior predictor of all-cause mortality in heart failure with reduced ejection fraction. *JACC Cardiovasc Imaging* 2015;**8**:1351–9.
46. Kalam K, Otahal P, Marwick TH. Prognostic implications of global LV dysfunction: a systematic review and meta-analysis of global longitudinal strain and ejection fraction. *Heart* 2014;**100**:1673–80.
47. Donal E, Thebault C, O'connor K, Veillard D, Rosca M, Pierard L *et al*. Impact of aortic stenosis on longitudinal myocardial deformation during exercise. *Eur J Echocardiogr* 2011;**12**:235–41.
48. Mignot A, Donal E, Zaroui A, Reant P, Salem A, Hamon C *et al*. Global longitudinal strain as a major predictor of cardiac events in patients with depressed left ventricular function: a multicenter study. *J Am Soc Echocardiogr* 2010;**23**:1019–24.
49. Thavendiranathan P, Grant AD, Negishi T, Plana JC, Popović ZB, Marwick TH. Reproducibility of echocardiographic techniques for sequential assessment of left ventricular ejection fraction and volumes: application to patients undergoing cancer chemotherapy. *J Am Coll Cardiol* 2013;**61**:77–84.
50. Nucifora G, Schuijff JD, Delgado V, Bertini M, Scholte AJ, Ng AC *et al*. Incremental value of subclinical left ventricular systolic dysfunction for the identification of patients with obstructive coronary artery disease. *Am Heart J* 2010;**159**:148–57.
51. Mollema SA, Delgado V, Bertini M, Antoni ML, Boersma E, Holman ER *et al*. Viability assessment with global left ventricular longitudinal strain predicts recovery of left ventricular function after acute myocardial infarction. *Circ Cardiovasc Imaging* 2010;**3**:15–23.
52. Ersbøll M, Valeur N, Mogensen UM, Andersen MJ, Møller JE, Velazquez EJ *et al*. Prediction of all-cause mortality and heart failure admissions from global left ventricular longitudinal strain in patients with acute myocardial infarction and preserved left ventricular ejection fraction. *J Am Coll Cardiol* 2013;**61**:2365–73.
53. Bertini M, Ng AC, Antoni ML, Nucifora G, Ewe SH, Auger D *et al*. Global longitudinal strain predicts long-term survival in patients with chronic ischemic cardiomyopathy. *Circ Cardiovasc Imaging* 2012;**5**:383–91.
54. Haugaa KH, Smedsrud MK, Steen T, Kongsgaard E, Loennechen JP, Skjaerpe T *et al*. Mechanical dispersion assessed by myocardial strain in patients after myocardial infarction for risk prediction of ventricular arrhythmia. *JACC Cardiovasc Imaging* 2010;**3**:247–56.
55. Di Salvo G, Rea A, Mormile A, Limongelli G, D'Andrea A, Pergola V *et al*. Usefulness of bidimensional strain imaging for predicting outcome in asymptomatic patients aged ≤16 years with isolated moderate to severe aortic regurgitation. *Am J Cardiol* 2012;**110**:1051–5.
56. Witkowski TG, Thomas JD, Debonnaire PJ, Delgado V, Hoke U, Ewe SH *et al*. Global longitudinal strain predicts left ventricular dysfunction after mitral valve repair. *Eur Heart J Cardiovasc Imaging* 2013;**14**:69–76.
57. Douglas PS, Morrow R, Ioli A, Reichel N. Left ventricular shape, afterload and survival in idiopathic dilated cardiomyopathy. *J Am Coll Cardiol* 1989;**13**:311–5.
58. Saguner AM, Vecchiati A, Baldinger SH, Rueger S, Medeiros-Domingo A, Mueller-Burri AS *et al*. Different prognostic value of functional right ventricular parameters in arrhythmogenic right ventricular cardiomyopathy/dysplasia. *Circ Cardiovasc Imaging* 2014;**7**:230–9.
59. Cardim N, Galderisi M, Edvardsen T, Plein S, Popescu BA, D'Andrea A *et al*. Role of multimodality cardiac imaging in the management of patients with hypertrophic cardiomyopathy: an expert consensus of the European Association of Cardiovascular Imaging Endorsed by the Saudi Heart Association. *Eur Heart J Cardiovasc Imaging* 2015;**16**:280.
60. Phelan D, Collier P, Thavendiranathan P, Popović ZB, Hanna M, Plana JC *et al*. Relative apical sparing of longitudinal strain using two-dimensional speckle-tracking echocardiography is both sensitive and specific for the diagnosis of cardiac amyloidosis. *Heart* 2012;**98**:1442–8.
61. Schiano-Lomoriello V, Galderisi M, Mele D, Esposito R, Cerciello G, Buonauro A *et al*. Longitudinal strain of left ventricular basal segments and E/e' ratio differentiate primary cardiac amyloidosis at presentation from hypertensive hypertrophy: an automated function imaging study. *Echocardiography* 2016;**33**:1335–43.
62. Haugaa KH, Basso C, Badano L, Bucciarelli-Ducci C, Cardim N, Gaemperli O *et al*. Comprehensive multi-modality imaging approach in arrhythmogenic cardiomyopathy—an expert consensus document of the European Association of Cardiovascular Imaging. *Eur Heart J Cardiovasc Imaging* 2017;**18**:237–53.
63. Marwick TH, Gillebert TC, Aurigemma G, Chirinos J, Derumeaux G, Galderisi M *et al*. Recommendations on the use of echocardiography in adult hypertension: a report from the European Association of Cardiovascular Imaging (EACVI) and the American Society of Echocardiography (ASE). *Eur Heart J Cardiovasc Imaging* 2015;**16**:577–605.
64. Levy D, Garrison RJ, Savage DD, Kannel WB, Castelli WP. Prognostic implications of echocardiographically determined left ventricular mass in the Framingham Heart Study. *N Engl J Med* 1990;**322**:1561–6.

